



ELSEVIER

Pathophysiology xxx (2009) xxx–xxx

 IJSP
 PATHOPHYSIOLOGY

www.elsevier.com/locate/pathophys

Cranial and postcranial skeletal variations induced in mouse embryos by mobile phone radiation

Adamantia F. Fragopoulou, Stauros L. Koussoulakos*, Lukas H. Margaritis

Department of Cell Biology and Biophysics, Faculty of Biology, N.&K. University of Athens, Panepistimiopolis 15784, Greece

Received 25 August 2009; received in revised form 26 September 2009; accepted 29 September 2009

Abstract

This study focuses on foetal development following mild daily exposure of pregnant mice to near field electromagnetic radiation emitted by a mobile phone. The investigation was motivated by the fact that the potentially hazardous electromagnetic radiation emitted by mobile phones is currently of tremendous public interest. Physically comparable pregnant mice were exposed to radiofrequency radiation GSM 900 MHz emitted by a mobile phone. Within 5 h after birth most cubs were fixed followed by double staining in toto, and conventional paraffin histology. Other cubs remained with their mothers until teeth eruption. Structural development was assessed by examining newborns for the presence of anomalies and/or variations in soft tissues and skeletal anatomy. Electromagnetic radiofrequency exposed newborns, externally examined, displayed a normal phenotype. Histochemical and histological studies, however, revealed variations in the exposed foetuses with respect to control ones concerning the ossification of cranial bones and thoracic cage ribs, as well as displacement of Meckelian cartilage. Littermates examined after teeth eruption displayed normal phenotypes. It is concluded that mild exposure to mobile phone radiation may affect, although transiently, mouse foetal development at the ossification level. The developmental variations observed could be explained by considering the different embryonic origin and mode of ossification of the affected skeletal elements.

© 2009 Elsevier Ireland Ltd. All rights reserved.

Keywords: Birth defects; Cranium; GSM; Ossification; Rib

1. Introduction

Over three billions of people in more than 200 countries are daily exposed consciously to electromagnetic fields (EMFs). Thousands of them and many others are also exposed to EMFs (e.g., base stations, wireless phones, and wi-fi) of varying strength unintentionally and sometimes unconsciously. Early data [1–3] indicated that EMFs may cause several disturbances in the physiology of many animal and plant species. The last decade has witnessed a dramatic increase in the extent and magnitude of the ambient EMFs. These fields are currently created mostly by mobile phone communication units and transmitting towers and are of major concern for the society because of their close proximity to human populations and sensitive somatic organs (e.g., acousticovestibular apparatus, brain, eyes, and testes). This concern is reflected into the huge literature (more than

50,000 scientific articles and books published) devoted to the biological effects of relevant radiofrequencies (RFs). Numerous reports support the notion that the biological risk from RFs [4–7] and from ELF (extremely low frequencies) [8] for people is negligible. However, most of the studies carried out thus far implicate EMFs with a wide spectrum of disturbances at the anatomical, physiological, cellular and molecular level both in humans and animal models [4,9–12, and references therein]. Since such controversies are not yet settled and remain still vivid, further evaluation of the impact of new technologies on the human body is essential in order to elucidate this issue and to impose, if needed, new regulations to further limit health risks.

Research performed worldwide seeks to evaluate any potential link between adverse health effects and the mobile phone radiation along with the associated mast stations [12,13]. Most studies focus on the effects of microwave radiation on near-source, high significance human organs [14–19]. There is no doubt that a great deal of the biological effects reported thus far are mainly caused by the part of the intrinsic

* Corresponding author. Tel.: +30 210 7274612; fax: +30 210 7274742.
 E-mail address: skoussou@biol.uoa.gr (S.L. Koussoulakos).

energy carried out by the RF microwaves and ELF's which is absorbed by and affects various tissues [20]. The extent and the magnitude of those biological effects depend largely (apart from the absorbed energy) on several physical parameters and biological variables, too (e.g., mass and geometry of the body, tissue type, subject grounding, local organ temperature, resonant frequency, and wave direction), which, due to their variability and unpredictability may lead frequently to controversial results [9,21–23].

For plausible reasons, most relevant experimental studies have been carried out on animal models. Admittedly, results of animal studies cannot be directly translated to human beings; however, the inevitable extrapolation of information gathered from animal studies to humans is well justified due to the plethora of anatomical similarities and the conservative nature of developmental and physiological processes [24]. Whereas the impact of EMFs on the exposed animals per se is extensively studied, little attention has so far been paid to the effects of EMF RFs on pregnancy [5,8,25–28], therefore concern has been expressed about the possible adverse effects of exposure to power–frequency EMFs on the development of the embryo and foetus. In a pioneer work, Leeka Kheifets' group has attributed behavioural defects on children born by mothers using mobile phones (MPs) during pregnancy [29]. However, since the results of both experimental and epidemiological studies are still inconclusive, further laboratory or mechanistic studies have been recommended.

The aim of the present investigation was to analyze the embryonic development of mice whose dams were exposed to mild RF EMFs emitted by a commercially available mobile phone in close contact with each animal. We have examined double-stained and cleared cranial and postcranial skeletal elements as well as paraffin histological sections of newborn mice after daily exposure of their pregnant mothers during the whole gestation. Results indicate a transient disturbance in the ossification process of various bones, which, however, recover postnatally.

2. Materials and methods

2.1. Animals and their housing

Healthy, young (two months old), nulliparus female mice (Balb/c *Mus musculus*, from Hellenic Pasteur Institute) from different litters and of the same age and size were quarantined in our laboratory for two weeks to assess their health and to allow them to acclimatize in a thermostatically maintained room ($22 \pm 1^\circ\text{C}$) and artificial illumination (12:12h light/dark photoperiod, lights on at 07:00 a.m.) with standard food, tap water ad libitum and frequent air changes. The animals were housed individually in small cages (9 cm \times 19 cm \times 12 cm). A conventional radio was playing in the animal room during acclimatization to imitate human voice required for the exposure session in order to stimulate mobile phone emission. All animal handling

and experimentation were carried out according to the ethics recommendation of the European Communities Council Directive.

2.2. Exposure of pregnant mice to electromagnetic field

One week before the exposure session, cages were transferred to the exposure room having identical conditions as the animal room. Five days before programmed mating all selected females were individually exposed (within their maintenance cages) to commercially available mobile phone whole body irradiation for 0 (control group: "exposed" to a battery-less mobile phone), 6 and 30 (experimental groups) min/day on successive days (time of day when the exposure occurred, between 12.00 and 14.00). The 5-day pre-pregnancy exposure was suggested to allow for a likely activation of intrinsic defense mechanisms (e.g., heat shock proteins, regional blood dynamic shifts) which have evolved by natural selection over millions of years of exposure to natural electromagnetic radiation. Additionally, since it is well documented that mouse immobilization is a stress-inducing factor, which influences the studied parameters [30] mice were allowed to live and move freely in their cages (internal dimensions, 9 cm \times 19 cm \times 12 cm), completely devoid of stress-inducing and maternotoxic factors.

After successful mating (vaginal smear, each female fertilized by a different male) pregnant mice were similarly exposed from the beginning of the pregnancy until term (total exposure time: 5 mice for zero, 7 for 126 and 7 for 630 min) to GSM 900 MHz. Foetuses in uterus grow in a milieu where complex factors, such as external noises or temperature fluctuations, possibly caused by the experimental procedures are not expected to influence intrauterine development. We preferred individual exposure in order to avoid electromagnetic shading. The exposure times were selected as representing a modest daily unintentional exposure to EMF RFs. The RF field for each mouse was emitted by a commercially available mobile phone with pulsed GSM (Global System for Mobile communications) at a frequency of 900 MHz microwaves during a normal call. The mobile phone was positioned at the middle of the cage base under a sheet of dielectric material which supports the electrostatic field while dissipating minimal energy in the form of heat. The EMF dosimetry produced by the mobile phone was constantly monitored by the Smart Fieldmeter, EMC Test Design, LLC, Newton, MA, USA and the recorded electrical field strength values within the cage, in the area where the mouse is moving, was 30 ± 5 V/m (volts/meter) depending on the sound level (speaking emission [31]).

The calculated specific absorption rate (SAR) was in the range of 0.6–0.94 W/kg, therefore thermal effects on dams and foetuses are not expected [note: the maximum SAR value for members of the public exposed to RF radiation at 900 MHz is set to 1.8 W/kg] [32]. The specific absorption

Table 1

Summary of experimental design and observed incidence of variations in newborn mice whose mothers were exposed to cell phone electromagnetic fields.

(a)	(b)	(c)	(d)	(e)	(f)	(g)	(h)
5 (0 min)	[5]	7 [5]	0 [0]	0 [0]	0 [0]	0 [0]	9 [5]
7 (6 min)	[7]	20 [7]	12 [7]	20 [7]	0 [0]	0 [0]	9 [7]
7 (30 min)	[7]	20 [7]	20 [7]	20 [7]	18 [7]	6 [4]	9 [7]

(a) Pregnant mice exposed to cell phone EMFs. (b) Litters. (c) Newborns randomly taken and double-stained. (d) Newborns with cranial bone variation. (e) Newborns with “white” rib part. (f) Newborns with displaced Meckelian cartilage. (g) Newborns with 8th rib attached to sternum. (h) Newborns left with their mothers.

- Historical control range for malformations or variations from various sources (e.g., MARTA and <http://phenome.jax.org/pub/cgi/phenome/mpdcgi?rtm=docs/home>) do not include data matching exactly with ours.

- All experimental data are significantly different from the control group using Fisher's exact test.

rate was calculated according to the formula:

$$\text{SAR} = \frac{\sigma E^2}{\rho} \quad (1)$$

where E is the electrical field, σ is the mean electrical conductivity and ρ is the mass density of the irradiated tissues. The parameters used for our mice were calculated according to [33] for adult mice, using Eq. (1) by applying the measured electrical field density 30 V/m, adopting $\sigma = 0.8$ S/m (average tissue value) and mass density $\rho = 1040$ kg/m³. Although the electromagnetic near field is practically inhomogeneous during the exposure period, all mice are considered as receiving the same average exposure level. Sham-exposed mice were kept strictly under the same conditions as irradiated mice, (a battery-less mobile phone and a playing radio included), but without any radiation present, as measured by field meters.

2.3. Experimental design

In order to evaluate the influence of the emitted EMF RF microwaves on the exposed pregnant mice, they were regularly weighted, and examined daily throughout the gestation period for general appearance and locomotor activity by cage-side observation. Their stereotyped behaviour was tested and their fixed motor patterns (complex rhythmic motor activities, e.g., tail and leg coordination during movements, walking, turning, rearing) were monitored. At birth, 27 newborns from 19 dams (9 from 0 min exposure, 9 from 6 min, 9 from 30 min) remained with their mothers until eruption of all their teeth. Forty-seven specimens of offspring (7 from 0 min, 20 from 6 min and 20 from 30 min) were fixed in 95% alcohol and processed (e.g., skin removal, and evisceration) for double, histochemical staining (Alcian blue—Sigma/Aldrich, Steinheim, Germany, for mucopolysaccharides, alizarin red S—Ferak, Berlin, Germany, for osseous tissue) [34] and clearing (in glycerine—AppliChem, Darmstadt, Germany) in order to reveal skeletal elements (Table 1). Sixteen newborns (4 from 0 min, 6 from 6 min, 6 from 30 min) were fixed in 5%

aqueous formaldehyde solution—Merck, Darmstadt, Germany, embedded in paraplast, sectioned at 5 μ m and stained by Domagk's method [35]. Briefly, this is a three-step staining procedure including nuclear red—Serva, Heidelberg, Germany, aniline blue—Merck, Darmstadt, Germany and orange G—Merck, Darmstadt, Germany. Before processing all fixed newborns were weighed, measured and outwardly inspected by binocular stereoscopy.

2.4. Statistical analysis

All analyses were two-tailed for a significance level of 5%. One-way analysis of variance (ANOVA) was applied for continuous maternal and foetal variables. The number of litters with developmental variations was analyzed by Fisher's exact test.

3. Results

3.1. Inspection of exposed pregnant mice

Inspection of the exposed and non-exposed pregnant mice was performed on a daily basis and no obvious differences were observed. The body mass increase was similar, the stereotyped behaviour and fixed motor patterns (complex rhythmic motor activities, e.g., tail and leg coordination during movements, walking, turning, and rearing) remained unchanged. In addition, the lack of any stress condition was estimated by the lack of any stretch attend or flatback approach.

3.2. Binocular inspection of newborns before and after in toto double staining

Inspection included overall body structure (limbs, digits, tail, ears, nostrils, whiskers, body weight and length). Under our chosen conditions, no externally displayed phenotypic differences were detected between experimental ($n = 70$) and control ($n = 20$) newborns. Alcohol-fixed newborns macerated in KOH and cleared in glycerine after whole body double staining for mucopolysaccharides and osseous tissue were carefully inspected under the dissecting microscope. Most of the skeletal elements (e.g., vertebrae and appendages) appeared normal (i.e., we do not count as “supernumerary” a very small spike on the vertebrae). Only a few cranial bones and thoracic cage ribs displayed some developmental variations. Table 1 summarizes experimental design and main results.

3.2.1. Cranial bones

The embryonic skull base (basicranium), a part of the cartilaginous neurocranium of neural crest origin, consists of a series of cartilages (e.g., basioccipital, basisphenoid, presphenoid, and ethmoid) separated by their synchondroses. Basicrania from control and experimental animals displayed

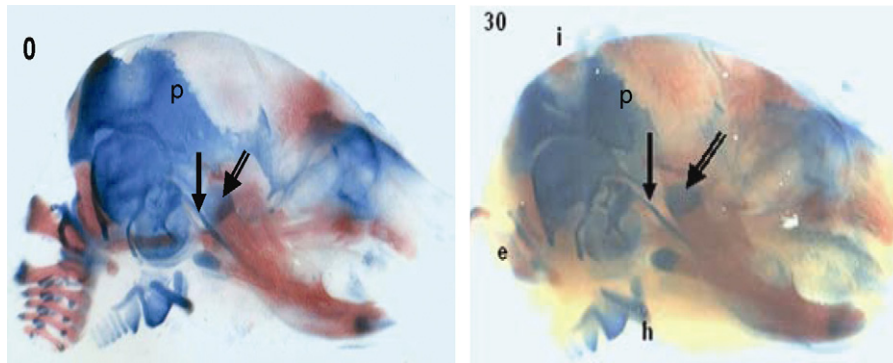


Fig. 1. Alizarin red S staining indicates that, 30 min daily exposure of mouse embryos for 21 days seems to “favour” intramembraneous ossification, as indicated by the phenotype of parietals (p), interparietal (i), exoccipital (e) and hyoid (h) bones. 0=0 min exposure, 30=30 min/day \times 21 days exposure. [Recall, that in the mouse, the interface between the frontal and parietal bones – the coronal suture – is a boundary between neural crest and mesoderm]. Note that Meckelian cartilage (single arrow, the blue line under the condyloid process) of control (0) animals runs closely apposed to the condyloid process (double arrow), whereas, in experimentals (30) is substantially displaced (single arrow) with respect to the condyloid process (double arrow). Otic capsule looks normal in both cases [variations in background color are due to picture editing to maximize contrast]. (For interpretation of the references to colour in this figure legend, the reader is referred to the web version of the article.)

exactly the same normal phenotype (therefore, data not shown), a fact which might imply that the cumulative rates of the absorbed energy do not affect relevant neural crest cell migration and homing, pattern formation and differentiation as well as basicranium formation and brain morphogenesis.

All skull roof bones derive by intramembraneous ossification, that is, mesenchyme in the deeper layer of the dermis differentiates directly to bone. The neural crest derived bones (frontal, squamosal, alisphenoid, and orbitosphenoid) of the experimental groups do not differ with respect to controls. In contrast, parietals, which derive from head mesoderm seem to respond to the irradiation schedule by increasing their mineralized parts, as revealed by the mere intense alizarin red S staining with respect to control animals, where the blue stain prevails. Similarly, the central part of the interparietal bone, although of neural crest origin, seems “more” ossified in experimental than in control animals (Fig. 1). Recall, that the central part of the interparietal, in contrast to the other sclerotomal occipital region bones, is of intramembraneous origin.

In the cartilaginous viscerocranium all skeletal elements (palatoquadrate, Meckelian cartilage, stapes, malleus, incus, and hyoid) are of neural crest origin (from posterior midbrain and rhombomeres 1 and 2) through the pharyngeal arches. The Meckelian cartilage runs forward immediately below and contacting the condyloid process (Fig. 1). At its proximal end the malleus and incus, two of the bones of the middle ear, are developed. In contrast, in the group of 30 min exposure a displacement in the direction of the Meckelian cartilage is obvious, as it runs in the middle between condyloid process and angle.

3.2.2. Thoracic ribs

In 40 examined experimental animals of the 6- and 30-min group, an unstained area was observed between red stained

proximal rib part and the blue stained distal rib part. Six out of twenty 30-min-exposed animals displayed the 8th left thoracic rib attached to the 6th sternebra, whereas, on the right hemithoracic cage the anatomy was normal (seven ribs articulating to the sternum) (Fig. 2). The ribs shown in Fig. 2 30 were de-glycerinated, de-hydrated, embedded in paraffin and sectioned at 5 μ m (Fig. 3). The blue and red stained areas (A and C, respectively) retain their staining, whereas, the middle, unstained part remains unstained (B), indicating perhaps lack of mucopolysaccharides, glucosaminoglycans and calcified tissues. However, continuation of the histological procedure (removal of paraffin, hydration, Domagk’s staining, Bs) reveals that even the rib part unable to react with alcian blue or alizarin red S during double staining in toto, now gives intense staining with aniline blue, indicating presence of collagen and reticular fibers.

3.3. Histological observations

Conventional paraffin histology (Domagk’s staining) performed on several control and experimental newborns (both simply preserved in formaldehyde and already double-stained) at places where double staining reveals variations (e.g., parietal bones) does not indicate any difference. In contrast, the unstained rib part, present only in cell-phone exposed animals, displays a highly vacuolated structure (Fig. 3Bs).

4. Discussion

4.1. General

The experimental and the epidemiological studies dealing with the effects of EMFs on biological systems and performed thus far worldwide are quite numerous, but their




Fig. 2. Thoracic cages from newborns whose mothers were exposed to whole body cell phone radiofrequency for 0 min (0), 6 min (6) and 30 min (30, 30m) daily for 5+21 days. Control specimens (0) indicate normal ribs (0 left) and a normal sternum (0 right) with six sternbrae and seven pairs of sternal ribs (costal cartilages) attached to them. The osseous part (red) is followed uninterruptedly by the cartilaginous (blue) one. (6): 6 min exposure: flat mount of a rib cage shows that between ossified (red) and cartilaginous (blue) zones of all ribs, a zone stained with neither alizarin red S nor alcian blue intervenes, indicating a disturbance in the ossification process in experimental animals. Although the right half of the thoracic cage (left to the reader) displays the physiological case (7 ribs articulating with the sternum), the left part of the thoracic cage displays 8 articulating ribs. (30): After 30 min exposure the unossified rib part intervening between bone and cartilage is more prominent. (30m): magnification of (30): A periosteal band (arrow) is formed throughout. (For interpretation of the references to colour in this figure legend, the reader is referred to the web version of the article.)

results are not unanimous, ranging from reserved to enthusiastic and “reveal” deleterious, harmless as well as beneficial effects [36]. An inherent difficulty in the assessment of the impact of electromagnetic radiation on the living matter originates from the fact that these studies are minimally comparable since they were performed on a plethora of different live animals, cultured cells, artificial models, materials and organs, using different sources, frequencies, modulation and strengths of the EMFs, whereas, the methods of assessment are frequently quite different. For example, our

results concerning disturbances only in some bones (cranial and ribs) coincide with several reports [27,37,38] but they do not agree with others [7], who found that their experimental design did not produce any biologically significant effect in either dams or foetuses. Despite the existing numerous contestations and doubts, there is a lot of data and evidence in favour of continuing similar studies. The main purpose of the present experimental work was simply to show that actually even modest exposure to EMFs may interfere with normal mammalian embryonic development.

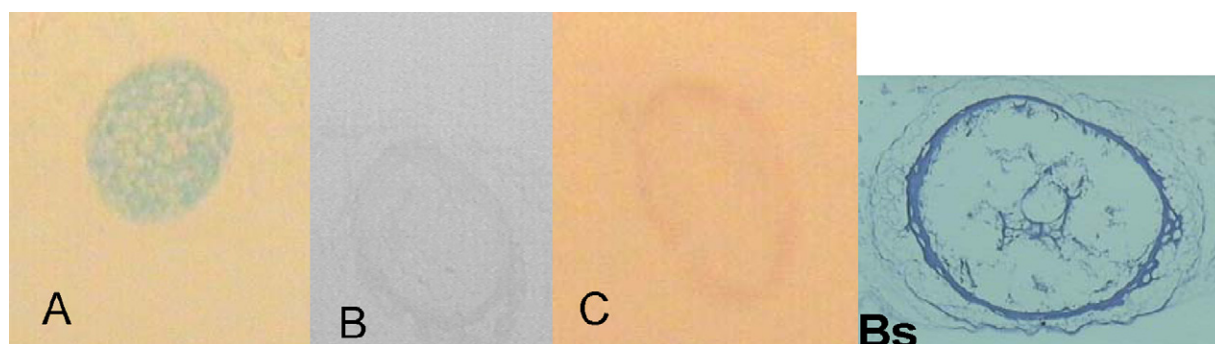


Fig. 3. Transverse microtome sections (5 μm) at distal (blue, A), medial (“unstained”, B), and proximal (rot, C) part of the ribs shown in Fig. 2.30. Those ribs were paraffinized, cut and photographed without any further treatment. Bs is a section of B after conventional histological treatment (deparaffinizing, Domagk's staining). B and Bs figures indicate that cell phone radiation affects the front of rib ossification [variations in background color are due to picture editing to maximize contrast]. (For interpretation of the references to colour in this figure legend, the reader is referred to the web version of the article.)

4.2. Exposure to electromagnetic fields

The rapid global increase in the use of wireless technology has been followed by a multiple increase in public concern regarding health and safety aspects. Many countries have already established safety guidelines and have set limits for the electric and magnetic field strengths for protecting their citizens from radio-frequency exposure. The basic exposure limits are frequently defined in terms of specific absorption rate (SAR), a surrogate measure used to quantify the body-core temperature rise induced by the absorption of the electromagnetic energy. Practically, SAR cannot be directly measured for any individual and is not accessible for routine evaluation of real-life exposure therefore SAR values are assessed by extrapolating data obtained primarily from expensive simulations in hominoid models imitating human structure and tissue composition and, tissue measurements in laboratories. However, proof is constantly accumulating that EMFs are very dangerous far below levels of heating (non-thermal effects) rendering thus SAR inadequate for imposing safety guidelines. Since such approximations are frequently oversimplified and SAR validity is being questioned by the latest calculation results [39–41], RF safety is most often determined and expressed in terms of power flux density (W/m^2). Besides, electrohypersensitivity, just emerging as a possibility to denote differential sensitivity of humans (so far) to EMFs is a fact. The only real-life quantities that can be measured somewhat easily are the free-field electric and magnetic field strengths. In addition, whole-body and specific tissue SAR values cannot be accurately calculated for the developing embryos in the present study because the density and the electrical conductivity of most embryonic and foetal structures (soft tissues, cartilage, bone) is constantly changing throughout development [23]. Apart from that, the progressive increase of the size of the developing organism, the alterations in foetal orientation relative to the electric and magnetic field vectors and in the direction of wave propagation make SAR calculations by numerical dosimetry extremely difficult and practically unreliable [42,43].

The ultimate aim of the present investigation was to provide some data which might be used profitably for the extrapolation of information derived from the laboratory animal studies to human health hazard and risk assessment. There is strong scientific rationale for using data from animal studies due to the conservative nature of developmental processes. Several approaches are being used in order to reveal the possible health effects from non-ionizing radiation: animal experiments, cell culture experiments, theoretical approaches and clinical as well as epidemiological studies of humans exposed to this type of radiation through mobile phone, wireless DECT, mast antennas, etc. Results on the effects of non-ionizing electromagnetic radiation on many aspects of animal physiology have been conflicting, some reports showing detrimental outcomes while others fail to document any harmful consequence [4,6,9,11,12]. How-

ever, since it is beyond doubt that magnetic fields as low as $1 \mu T$ can induce biological effects, exposure of a person to a conventional mobile phone that peaks at several tens of microtesla may induce harmful effects [44]. The “on” mode of most cell phones exhibits extremely low frequencies emission at 50–100 nT and, 5 nT in “stand-by” mode. The background environmental level is estimated to a value of 2 nT. Moreover, GSM mobile phones emit both pulsed radio waves (from the antenna) and ELF (from the battery circuits) that are especially dangerous for biological tissues. The vast majority of the relative investigations focus on near-source organs such as brain, eye and ear, and look for disturbances mainly in brain functions and anatomy (learning, memory, blood–brain barrier, neuron death, etc. [3,14,45]) of the exposed adults, paying little attention to embryonic development [27,28,38,46]. However, it is recognized that additional investigations are needed to acquire satisfactory knowledge for a rigorous and comprehensive risk assessment. Our present study aims to provide information concerning prenatal development and shows that even modest exposure levels of pregnant mice to electromagnetic fields emitted by commercially available mobile phone affects the normal developmental procedures, as indicated by the observed morphological variations. Under our “mild” experimental conditions these effects are not permanent, since the animals seem to recover postnatally.

4.3. Binocular inspection of newborns and 35-day-old cubs

External examination under the dissecting microscope and measurements revealed lack of any difference between experimental and control animals. [We consider as quantitative “different” a value far from the mean of the control group by 2 standard deviations.] In this respect, our findings are in full agreement with those reported by other laboratories [27,37,38].

4.4. Whole newborn double staining

We have focused our attention mainly on calcifying structures because they are well defined and variations are readily discernible. In addition, since their electrical conductivity (in S/m) is much lower than in other tissues (e.g., 0.20–0.82 for bones, 0.52–1.79 for cartilage and 0.07–0.04 for teeth) and their density (in kg/m^3) is much higher (1950, 1100, 2160, respectively), by applying SAR equation ($SAR = \sigma E^2 / \rho$), thermal effects can be excluded [23,32].

Newborns cleared in glycerine after whole body double staining for mucopolysaccharides/cartilage and osseous tissue were carefully inspected under the dissecting microscope. Our results clearly show that even modest exposure (e.g., only 6 min daily for 21 days, see Table 1) is sufficient to interfere with the normal mouse developmental process causing several variations affecting mainly osteogenesis. In this

respect, our main result, that only a few cranial bones and thoracic cage ribs displayed some developmental variations are in full agreement with those of [24]. These effects are probably quantitative, as deduced by the increased seriousness at 30 min exposure window. However, these effects are not permanent, as indicated by the normal osteogenic pattern displayed by 35-day-old mice; it is since long known that offspring with mild ossification delays are likely to recover [47]. Several studies have examined the potential role of maternal toxicity or stress on the development of skeletal variations in their offspring. Some investigators maintain that many skeletal variations are the secondary results of maternal toxicity [48,49]. This is not our case since all animals, both control and experimental were selected in the same manner and left freely moving in their cages, without handling or any restriction, the latter to obviate any stress-related exposure module confinement effects.

Most of the 41 mouse cranial bones derive from cranial neural crest cells [50]; the rest are of paraxial mesoderm origin. Some of them (basicranium) display endochondral, whereas the others (cranial vault and facial bones) exhibit intramembranous mode of ossification [51]. Cranial bone development and growth is influenced by brain growth, meaning that their final shape and size follow that of the brain. These skeletal elements play key roles in integrated craniofacial morphogenesis. Due to the highly complicated nature of head development, craniofacial dysplasias alone account for numerous dysmorphic features. Therefore, any deviation or delay in the development of embryonic cranial skeletal elements constitutes a type of skeletal abnormality or variation met frequently in studies of environmental risks assessment and might unveil interference of an external cause.

We consider that the changes we have observed are due to the irradiation effect and it is unlikely to reflect normal variation range, since making a MARTA (Middle Atlantic Reproduction and Technology Association) survey did not reveal any such information.

Mice normally possess 13 pairs of thoracic cage ribs. The upper seven pairs are connected to the sternum by seven pairs of costal cartilages (six intervening sternbrae). The rest six pairs are free. Each mammalian thoracic cage rib consists of three constituents, the proximal part, the vertebral part and the sternal part (possibly, all three of sclerotome origin). At ED (embryonic day) 12, the entire mouse rib consists of cartilage, but at ED 14 the rib cartilage template becomes invaded by blood vessels, osteoclasts and osteoblasts and a growth plate is established dorsally and ossification begins, proceeding ventrally towards the sternum.

When ossification centres are established in the normal rib bone development, the chondrocytes hypertrophy, glyco-gen accumulates within them, and their cytoplasm becomes highly vacuolated. As the chondrocytes hypertrophy, there is an enlargement of their lacunae at the expense of the intervening cartilage matrix, which is gradually reduced to thin fenestrated septa and irregularly shaped spicules. The remaining hyaline matrix in the region of hypertrophic cartilage

cells becomes calcifiable, and small granular aggregations and nests of crystals of calcium phosphate are deposited within it. The portions stained with neither alcian blue nor alizarin red S in the ossification centres of normal foetuses may correspond to the vacuolated cytoplasm of chondrocytes or their enlarged lacunae. Cell-phone-treated foetuses had large and irregular unstained portions compared to normal foetuses. It is suggested that EMF RF inhibits bone deposition, when the primary ossification centres are being formed. It must be stressed that inhibition of bone deposition is also described during rat embryonic development after exposure to carbon tetrachloride, 1,1-dichloroethane and methyl ethyl ketone [52]. Understanding the etiology and degree of delayed ossification or growth retardation may be important in making decisions about the importance of the results for human development.

Under this scope it is important to mention Leeka Kheifets' recent report on behavioural abnormalities observed in children born by mothers using mobile phone during pregnancy [29].

The key question is: do living organisms react upon their exposure to electromagnetic fields at radiofrequencies and above? The major issue is that unlike other forms of exposure, the use of the mobile phone takes place near the user's head and therefore the elucidation of the cellular, molecular and behavioural effects are of utmost importance, especially since the majority of future users are the current teenagers.

5. Conclusion

The worldwide use of cell phones has brought focus on the potential for radio frequency (microwave) electromagnetic radiation to elicit biological stress responses, in association with detrimental effects of this to human health. However, the so far existing data is contradictory enough, a fact which hampers an undisputable evaluation of the harmful effects of the microwaves at the level of the cell, the organ, the individual and the population. Many of the related studies are flawed by inconsistencies in exposure models, cell types used and the independent reproducibility of the findings. Further, the paucity of evidence from in vivo experimentation is largely conflicting.

In the present study we have used a statistically sufficient number of experimental animals, subjected to an exposure whose duration and strength might represent a minimal human exposure level to MP radiation. It was clearly indicated that even such weak exposure conditions may affect, although transiently, mammalian embryonic development. Specifically, embryonic development taking place in the presence of mild electromagnetic field throughout the gestation period for just 6 min daily, affects fetuses reversibly on their bone formation. This is caused possibly through the interaction of the microwaves and/or the ELF components of mobile phone radiation with crucial molecules and ions being involved in embryogenesis.

Acknowledgement

We acknowledge the financial contribution of the Special Account for Research Grants from the N.&K. University of Athens.

References

- [1] R. Reiter, Biological effects of electric and electromagnetic fields, *Prog. Biometeorol.* 1 (1A) (1974) 329–334, 662–663.
- [2] C.F. Blackman, S.G. Benane, L.S. Kinney, D.E. House, W.T. Joines, Effects of ELF fields on calcium ion efflux from brain tissue in vitro, *Radiat. Res.* 92 (1982) 510–520.
- [3] E.B. Lyskov, J. Juutilainen, V. Jousmäki, J. Partanen, S. Medvedev, O. Hänninen, Effects of 45-Hz magnetic fields on the functional state of the human brain, *Bioelectromagnetics* 14 (2) (1993) 87–95.
- [4] G.J. Hyland, Physics and biology of mobile telephony, *Lancet* 356 (9244) (2000) 1833–1836.
- [5] A. Papparini, P. Rossi, G. Gianfranceschi, V. Brugaletta, R. Falsaperla, P. De Luca, V. Romano Spica, No evidence of major transcriptional changes in the brain of mice exposed to 1800 MHz GSM signal, *Bioelectromagnetics* 29 (4) (2008) 312–323.
- [6] A. Tuffs, Mobile phones do not pose health risk, German survey shows, *BMJ* 336 (7659) (2008) 1461.
- [7] K. Ogawa, K. Nabae, J. Wang, K. Wake, S.I. Watanabe, M. Kawabe, O. Fujiwara, S. Takahashi, T. Ichihara, S. Tamano, T. Shirai, Effects of gestational exposure to 1.95-GHz W-CDMA signals for IMT-2000 cellular phones: lack of embryotoxicity and teratogenicity in rats, *Bioelectromagnetics* 30 (3) (2009) 205–212.
- [8] M.K. Chung, J.C. Kim, S.H. Myung, D.I. Lee, Developmental toxicity evaluation of ELF magnetic fields in Sprague–Dawley rats, *Bioelectromagnetics* 24 (4) (2003) 231–240.
- [9] L.G. Salford, A.E. Brun, J.L. Eberhardt, L. Malmgren, B.R. Persson, Nerve cell damage in mammalian brain after exposure to microwaves from GSM mobile phones, *Environ. Health Perspect.* 111 (7) (2003) 881–883 (discussion A408).
- [10] J.C. Lin, Studies on microwaves in medicine and biology: from snails to humans, *Bioelectromagnetics* 25 (3) (2004) 146–159.
- [11] I.Y. Belyaev, Y.G. Grigoriev, Problems in assessment of risks from exposures to microwaves of mobile communication, *Radiat. Biol. Radioecol.* 47 (6) (2007) 727–732.
- [12] L. Hardell, C. Sage, Biological effects from electromagnetic field exposure and public exposure standards, *Biomed. Pharmacother.* 62 (2) (2008) 104–109.
- [13] K. Makker, A. Varghese, N.R. Desai, R. Mouradi, A. Agarwal, Cell phones: modern man's nemesis? *Reprod. Biomed. Online* 18 (1) (2009) 148–157.
- [14] T. Kumlin, H. Iivonen, P. Miettinen, A. Juvonen, T. van Groen, L. Puranen, R. Pitkäaho, J. Juutilainen, H. Tanila, Mobile phone radiation and the developing brain: behavioral and morphological effects in juvenile rats, *Radiat. Res.* 168 (4) (2007) 471–479.
- [15] D.E. Bamiau, B. Ceranic, R. Cox, H. Watt, P. Chadwick, L.M. Luxon, Mobile telephone use effects on peripheral audiovestibular function: a case–control study, *Bioelectromagnetics* 29 (2) (2008) 108–117.
- [16] J.L. Eberhardt, B.R. Persson, A.E. Brun, L.G. Salford, L.O. Malmgren, Blood–brain barrier permeability and nerve cell damage in rat brain 14 and 28 days after exposure to microwaves from GSM mobile phones, *Electromagn. Biol. Med.* 27 (3) (2008) 215–229.
- [17] N. Küçer, Some ocular symptoms experienced by users of mobile phones, *Electromagn. Biol. Med.* 27 (2) (2008) 205–209.
- [18] S. Sadetzki, A. Chetrit, A. Jarus-Hakak, E. Cardis, Y. Deutch, S. Duvdevani, A. Zultan, I. Novikov, L. Freedman, M. Wolf, Cellular phone use and risk of benign and malignant parotid gland tumors—a nationwide case–control study, *Am. J. Epidemiol.* 167 (4) (2008) 457–467.
- [19] P. Huttunen, O. Hänninen, R. Myllylä, FM-radio and TV tower signals can cause spontaneous hand movements near moving RF reflector, *Pathophysiology* 16 (2–3) (2009) 201–204.
- [20] C.F. Blackman, Cell phone radiation: evidence from ELF and RF studies supporting more inclusive risk identification and assessment, *Pathophysiology* 16 (1) (2009) 205–216.
- [21] B. Cosquer, A.P. Vasconcelos, J. Fröhlich, J.C. Cassel, Blood–brain barrier and electromagnetic fields: effects of scopolamine methylbromide on working memory after whole-body exposure to 2.45 GHz microwaves in rats, *Behav. Brain Res.* 161 (2) (2005) 229–237.
- [22] R.L. McIntosh, V. Anderson, R.J. McKenzie, A numerical evaluation of SAR distribution and temperature changes around a metallic plate in the head of a RF exposed worker, *Bioelectromagnetics* 26 (5) (2005) 377–388.
- [23] A. Razmadze, L. Shoshiashvili, D. Kakulia, R. Zaridze, G. Bit-Babik, A. Faraone, Influence of specific absorption rate averaging schemes on correlation between mass-averaged specific absorption rate and temperature rise, *Electromagnetics* 29 (2009) 77–90.
- [24] R.W. Tyl, N. Chernoff, J.M. Rogers, Altered axial skeletal development, *Birth Defects Res. B: Dev. Reprod. Toxicol.* 80 (6) (2007) 451–472.
- [25] M.E. Chernovetz, D.R. Justesen, N.W. King, J.E. Wagner, Teratology, survival, and reversal learning after fetal irradiation of mice by 2450-MHz microwave energy, *J. Microw. Power* 10 (4) (1975) 391–409.
- [26] E. Berman, J.B. Kinn, H.B. Carter, Observations of mouse fetuses after irradiation with 2.45 GHz microwaves, *Health Phys.* 35 (6) (1978) 791–801.
- [27] I.N. Magras, T.D. Xenos, RF radiation-induced changes in the prenatal development of mice, *Bioelectromagnetics* 18 (6) (1997) 455–461.
- [28] R.P. Jensh, Behavioral teratologic studies using microwave radiation: is there an increased risk from exposure to cellular phones and microwave ovens? *Reprod. Toxicol.* 11 (4) (1997) 601–611.
- [29] H.A. Divan, L. Kheifets, C. Obel, J. Olsen, Prenatal and postnatal exposure to cell phone use and behavioral problems in children, *Epidemiology* 19 (4) (2008) 523–529.
- [30] G. Fernández, M.-P. Mena, A. Arnau, O. Sánchez, M. Soley, I. Ramírez, Immobilization stress induces c-Fos accumulation in liver, *Cell Stress Chaperones* 5 (4) (2000) 306–312.
- [31] D.J. Panagopoulos, L.H. Margaritis, Mobile telephone radiation effects on living organisms, in: A.C. Harper, R.V. Bures (Eds.), *Mobile Telephones, Networks, Applications and Performance*, Nova Science Publishers, 2008, ISBN 978-1-60456-436-5, pp. 107–149.
- [32] ICNIRP, Guidelines for limiting exposure to time-varying electric, magnetic and electromagnetic fields (up to 300 GHz), *Health Phys.* 74 (1998) 494–522.
- [33] A. Peyman, A.A. Rezazadeh, C. Gabriel, Changes in the dielectric properties of rat tissue as a function of age at microwave frequencies, *Phys. Med. Biol.* 46 (2001) 1617–1629.
- [34] C. Kimmel, C. Trammel, A rapid procedure for routine double staining of cartilage and bone in fetal and adult animals, *Stain Technol.* 56 (1981) 271–273.
- [35] B. Romeis, *Mikroskopische Technik*, Urban & Schwarzenberg, Muenchen, 1948.
- [36] M. Koivisto, A. Revonsuo, C. Krause, C. Haarala, L. Sillanmäki, M. Laine, H. Hämäläinen, Effects of 902 MHz electromagnetic field emitted by cellular telephones on response times in humans, *Neuroreport* 11 (2) (2000) 413–415.
- [37] R.P. Jensh, I. Weinberg, R.L. Brent, Teratologic studies of prenatal exposure of rats to 915 MHz microwave radiation, *Radiat. Res.* 92 (1) (1982) 160–171.
- [38] A. Pырpasopoulou, V. Kotoula, A. Cheva, P. Hytiroglou, E. Nikolakaki, I.N. Magras, T.D. Xenos, T.D. Tsioukakis, G. Karkavelas, Bone morphogenetic protein expression in newborn rat kidneys after prenatal exposure to radiofrequency radiation, *Bioelectromagnetics* 25 (3) (2004) 216–227.
- [39] J. Wang, O. Fujiwara, S. Kodera, S. Watanabe, FDTD calculation of whole-body average SAR in adult and child models for frequencies from 30 MHz to 3 GHz, *Phys. Med. Biol.* 51 (2006) 4119–4127.

- [40] T. Toivonen, T. Toivo, L. Puranen, K. Jokela, Specific absorption rate and electric field measurements in the near field of six mobile phone base station antennas, *Bioelectromagnetics* 30 (4) (2009) 307–312.
- [41] R.P. Findlay, P.J. Dimbylow, Spatial averaging of fields from half-wave dipole antennas and corresponding SAR calculations in the NORMAN human voxel model between 65 MHz and 2 GHz, *Phys. Med. Biol.* 54 (8) (2009) 2437–2447.
- [42] C.-K. Chou, Use of heating rate and specific absorption rate in the hyperthermia clinic, *Int. J. Hyperthermia* 6 (2) (1990) 367–370.
- [43] P.J. Dimbylow, A. Hirata, T. Nagaoka, Intercomparison of whole-body averaged SAR in European and Japanese voxel phantoms, *Phys. Med. Biol.* 53 (20) (2008) 5883–5897.
- [44] C. Sage, O. Johansson, S.A. Sage, Personal digital assistant (PDA) cell phone units produce elevated extremely-low frequency electromagnetic field emissions, *Bioelectromagnetics* 28 (5) (2007) 386–392.
- [45] E. Odaci, O. Bas, S. Kaplan, Effects of prenatal exposure to a 900 MHz electromagnetic field on the dentate gyrus of rats: a stereological and histopathological study, *Brain Res.* 1238 (2008) 224–229.
- [46] A.F. Pourslis, Reproductive and developmental effects of EMF on vertebrate animal models, *Pathophysiology* 16 (2–3) (2009) 179–189.
- [47] A.K. Palmer, R.J. Kavlock, Consensus workshop on the evaluation of maternal and developmental toxicity work group II report: study design considerations, *Teratog. Carcinog. Mutagen.* 7 (3) (1987) 311–319.
- [48] K.S. Khera, Maternal toxicity: a possible etiological factor in embryo–fetal deaths and fetal malformations of rodent–rabbit species, *Teratology* 31 (1) (1985) 129–153.
- [49] R.M. McClain, E. Wolz, A. Davidovich, J. Edwards, J. Bausch, Reproductive safety studies with genistein in rats, *Food Chem. Toxicol.* 45 (8) (2007) 1319–1332.
- [50] L.A. Opperman, Cranial sutures as intramembranous bone growth sites, *Dev. Dyn.* 219 (4) (2000) 472–485.
- [51] R.A. Hilloowala, R.B. Trent, R.G. Pifer, Interrelationships of brain, cranial base and mandible, *Cranio* 16 (1998) 267–274.
- [52] B.A. Schwetz, B.K. Leong, P.J. Gehring, Embryo- and fetotoxicity of inhaled carbon tetrachloride, 1,1-dichloroethane and methyl ethyl ketone in rats, *Toxicol. Appl. Pharmacol.* 28 (3) (1974) 452–464.